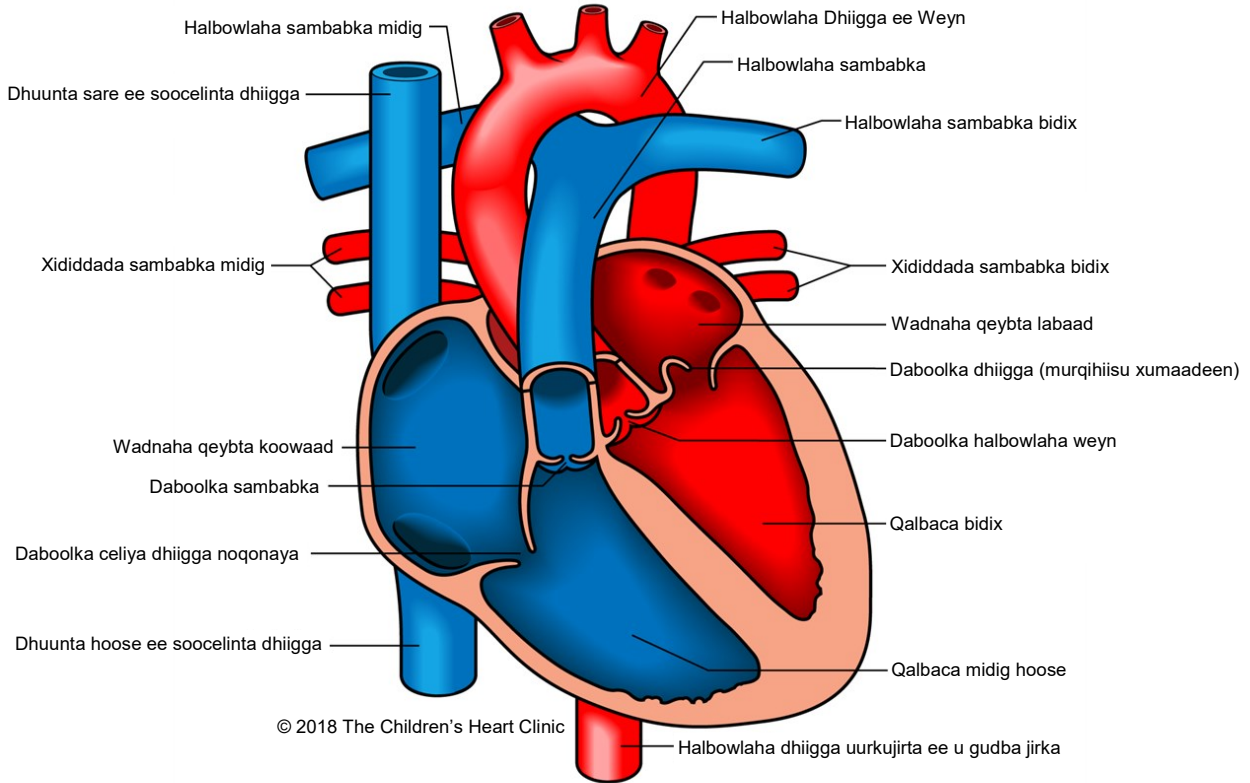
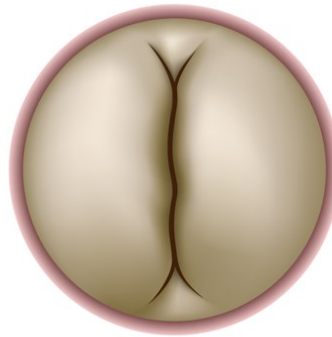


Mitral Valve Prolapse

Daboolka Dhiigga Muruqiisu Xumaaday



**Daboolka Dhiigga
Caadiga**



**Daboolka Dhiigga
Muruqiisu Xumaaday**



Ogeysiis:

The Children's Heart Clinic 2530 Chicago Avenue S, Ste 500, Minneapolis, MN 55404
612-813-8800 * Toll Free: 1-800-938-0301 * Fax: 612-813-8825
Children's Hospital of Minnesota, 2525 Chicago Avenue S, Minneapolis, MN 55404

Daboolka Dhiigga Muruqiisu Xumaaday Mitral Valve Prolapse (MVP)

Mitral valve prolapse (Daboolka dhiigga muruqiisu xumaaday) waa cillad aan caadi ahayn oo ku dhacda daboolka u dhexeeya qalbacyada bidix iyo bidix ee wadnaha oo keena dibu-noqod ku dhaca dhiigga (dabool dhiigga deynaya) oo ka soo baxa qalbaca bidix oo u gudba qalbaca bidix. Badanaa waxa sababa daboolka murqaha liifadda ah oo adkaada ama ku sii fida gudaha (ama salka) daboolka. Baaha dhibaatadan waxay la korortaa da'da oo waxaa badanaa lagu arkaa carruurta waaweyn, dhallinta, iyo qaangaarka. Waxaa mararka qaarkood lala xiriiriyaa xanuun ah xuubka jirka hoose ku fidsan sida cilladda Marfan ama Ehlers-Danlos. Waxa kale oo laga yaabaa in ay la xiriirto cilladaha kale ee wadnaha sida duleelka bartanka ah atrial septal sekundum (duleelka darbiga kore ama ASD), ventricular septal ventricular (cilladda duleelka darbiga qalbaca hoose ama VSD) iyo/ama Ebstein daboolka dhiigga ee aan caadiga ahayn.

Wiisiteynta/Calaamadaha Jirka:

- Carruurta laga helo daboolka dhiigga muruqiisu xumaaday wax calaamado ah ma laha.
- Wadne xanuun yar oo aan caddayn, xanuun laabta ah oo aan darneyn, oo inta badan lagu tilmaamo mindi iyo oo ah cirifka sare ee wadnaha, ayaa mararka qaarkood dhacaya.
- Wadnaha oo garaacma in yar istaaga ayaa marar dhif ah dhici kara.
- Carruurta qaba MVP waxaa caadi ahaan loo arkaa in ay noqdaan caato oo waxaa u badan cillado ah khalfoofka ama lafaha jirka, gaar ahaan habka qallooca lafdhabarta
- Sharqan laga maqli karo bartanka cabbirka dhiigga kore oo leh ama aan lahayn guux dambe ayaa ka jireysa figta sare oo waxaa laga yaabaa in la dareemo. Calaamadahaas waxaa mararka qaarkood lagu soo saaraa siyaabo kala duwan sida neefta oo la isku cesho ama in la fadhi laga kaco oo la istaago.

Cilladsheegid:

- ECG: Badanaa waa caadi, mararka qaarkood ayaa lagu arkaa mowjadaha-T oo noqda mid kala jeeda dhanka hoose. Supraventricular tachycardia (Qalbacyada hoose oo degdeg u garaacma ama SVT), isku-dhegid qalbaca kore oo degdeg ah ama isku-dhegid qalbaca hoose oo degdega ah ma aha wax dhaca laakiin waa ay dhici kartaa.
- X-Ray laabta: Caadi ahaan lama arki karo markuu cabbirka wadnuhu caadi yahay haddii aysan jirin daboolka muruqa oo dhiigga si daran u daadinaya oo ay sababtay ballaarnida bidix ee qalbaca kore. Waxaa laga yaabaa in la arko cillado kale oo ah khalfoofka.
- Uultarasawanka wadnaha: Cilladsheegid.

Maareynta/Daaweynta Caafimaadka:

- Haddii aysan calaamado jirin, daaweyn ama wax dhaqdhaqaaq ah looma baahan doona.
- Daawooyinka wadnaha ka dhiga gaabis, sida propranolol ama atenolol, ayaa la isticmaali karaa haddii ay jiraan calaamado ah garaaca wadnaha, madax-wareer, dawakhaad, ama wadmaha ayaa jiraya heerka labaad ee garaacista wadnaha ee aan caadiga ahayn.
- Haddii calaamadaha iyo xaalku uusan caadi ku ahayn EKG sida garaacaha wadnaha oo aan caadi ahayn, ama haddii ay jirto cillad shaqada qalbaca bidix, waxaa lagu talinayaa in la xaddido dhaqdhaqaaq fudud ama ah xoogga yar.
- Bacterial endocarditis prophylaxis (Bakteeriyada infakshanka wadnaha ama SBE) ka hor qalliinka ilkaha ma lagula talinayo badanaa ilmaha qaba MVP.
- Qalliinka hagaajinta ama beddelka daboolka ayaa ah mid naadir ah oo la tilmaamo oo keliya xaaladaha daran ee daboolka dhiigga daadinaya.

Natijoooyinka Mustaqbalka-Fog/La-socoshada:

- Wakhtiga iyo inta jeer ee la-socoshada waxay ku xiran yihiin sida fiican ee uu daboolku u shaqeeyo.
- Natijoooyinka mustaqbalka-fog guud ahaan waa kuwo aad u wanaagsan.
- Waxaa jira khatar weyn oo ku dhacaysa wadnaha iyo xadiddada wadnaha ee iyada oo aan lahayn sabab cad; daraasado ayaa hadda socda si loogu go'aamiyo arrimaha khatarta ah in natijada la helayo.