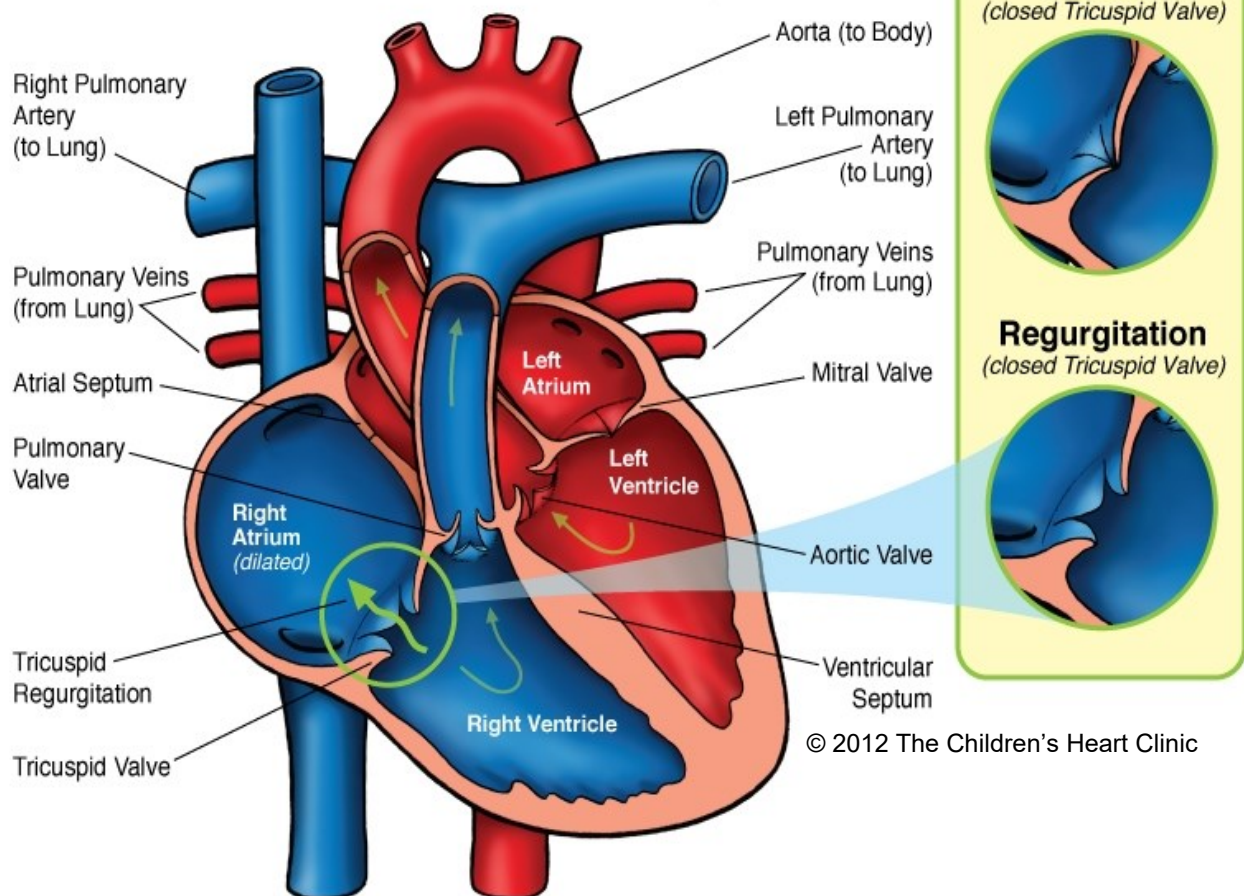


Tricuspid Regurgitation



© 2012 The Children's Heart Clinic

Notes:

The Children's Heart Clinic 2530 Chicago Avenue S, Ste 500, Minneapolis, MN 55404
612-813-8800 * Toll Free: 1-800-938-0301 * Fax: 612-813-8825
Children's Hospital of Minnesota, 2525 Chicago Avenue S, Minneapolis, MN 55404

Tricuspid Regurgitation (TR) or Insufficiency

In the normal heart, blood returns to the right atrium from the body via the superior and inferior vena cavae. Blood then flows from the right atria to the right ventricle across the tricuspid valve. The tricuspid valve has three leaflets that allow the valve to open and bring blood into the right ventricle, then shut like a gate to allow for right ventricular contraction. Blood normally goes through the valve in mainly one direction, from the right atrium to the right ventricle, with no or minimal regurgitation (back flow) or insufficiency. Trace, trivial, mild, or “physiologic TR” is a small amount of regurgitation that is considered to be a normal finding and is not cause for concern.

Tricuspid regurgitation (TR) refers to the regurgitation of blood from the right ventricle to the right atrium due to failure of the valve to close properly during systole. This can occur if right ventricular pressures are very high due to downstream obstruction such as in the setting of pulmonary hypertension or significant pulmonary stenosis or atresia. TR is common in children with single ventricle physiology, where the right ventricle is the main pumping chamber to the body because the blood pressure in the body is higher than the anatomic right ventricle is used to pumping against. TR may also occur if the tricuspid valve itself is abnormal, such as in Ebstein’s anomaly, tricuspid valve dysplasia, or in the setting of infection (endocarditis, rheumatic fever). When the tricuspid insufficiency is significant, this can lead to dilation (enlargement) of the right atrium. In addition, right ventricular enlargement can occur due to the volume load of TR on the ventricle.

Physical Exam/Symptoms:

- If the TR is physiologic in nature, it is not audible and there are no resulting symptoms because it is a normal finding.
- Significant TR (moderate or severe) can lead to symptoms of right-sided heart failure such as ascites (fluid in the abdomen), hepatomegaly (liver enlargement), peripheral edema (swelling and fluid retention), fatigue, tachypnea (rapid breathing), and eventual weight loss may occur.
- A low-pitched systolic regurgitant murmur may be audible at the left and right lower sternal borders.
- A diastolic rumble and loud S3 may also be heard and reflects the increased volume of flow across the tricuspid valve.
- Pulsation of the liver and neck veins may be present if TR is severe and central venous pressure is elevated.

Diagnostics:

- Chest X-ray: May be normal or show varying degrees of cardiomegaly (enlargement of the heart) due to right atrial and/or ventricular enlargement.
- EKG: May be normal or show right atrial enlargement (RAE), right ventricular enlargement (RVE), or right bundle branch block (RBBB).
- Echocardiogram: Diagnostic.

Medical Management/Treatment:

- Treatment of the underlying cause is the primary goal.
- Diuretics (Lasix) may be used to decrease edema in the liver and lower extremities.
- Afterload reducing agents (enalapril, captopril) are not well studied in right-sided atrioventricular valve disease, but are often used in single ventricle patients with TR.
- Surgical repair of the valve may be warranted. Your cardiologist will discuss surgical options with you, if applicable.
- In the setting of significant right atrial enlargement, arrhythmias such as atrial fibrillation or flutter or supraventricular tachycardia may occur, necessitating medication or catheter-based intervention (ablation).
- Children with mild TR who are otherwise healthy do not require long-term cardiology follow up.
- Life-long cardiology follow up is necessary for individuals with moderate to severe TR regardless of cause and presence or absence of accompanying congenital heart disease.

Long-Term Outcomes:

- Individuals who have mild-moderate TR should have, in general, normal life expectancy in the absence of other congenital heart disease or co-morbidities.
- Long-term prognosis is dependent on the underlying cause and not necessarily the severity of TR.