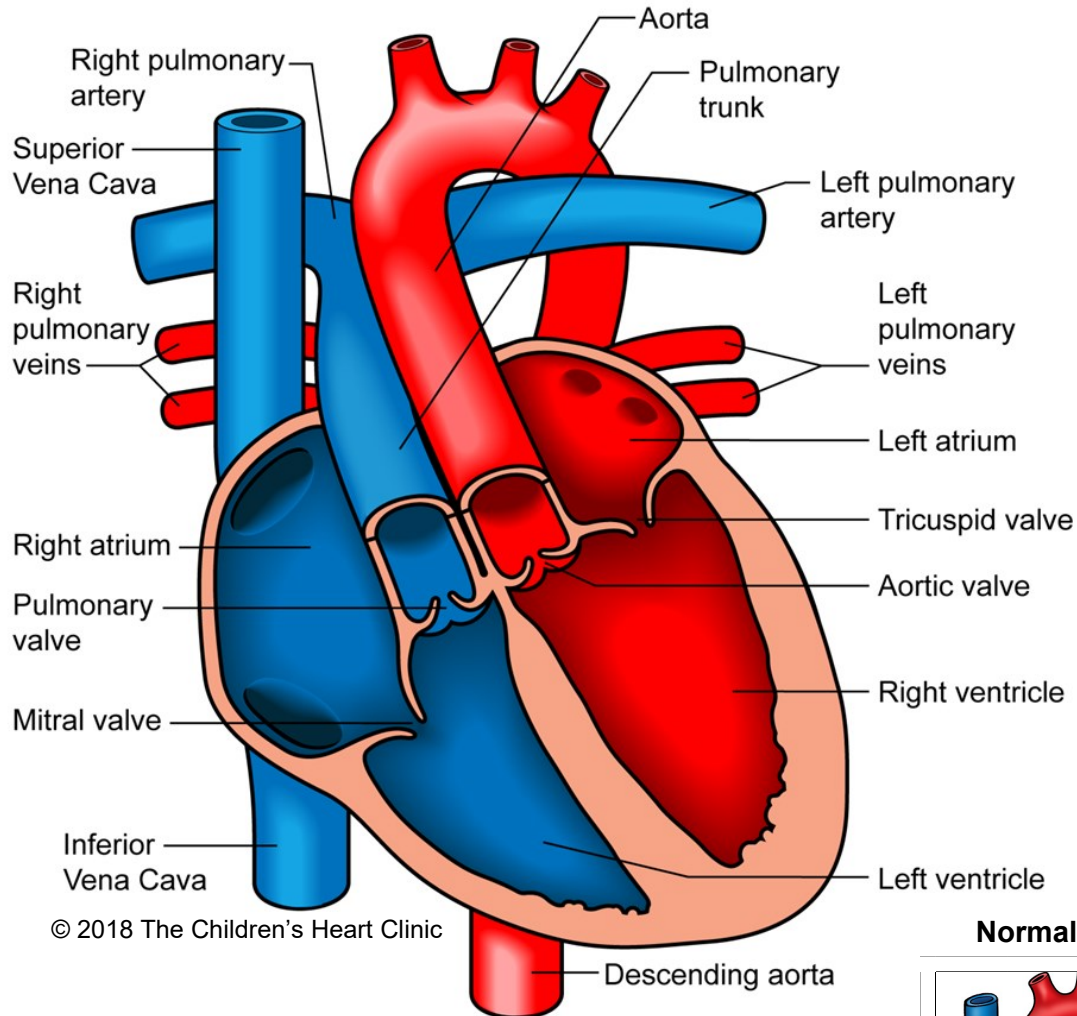
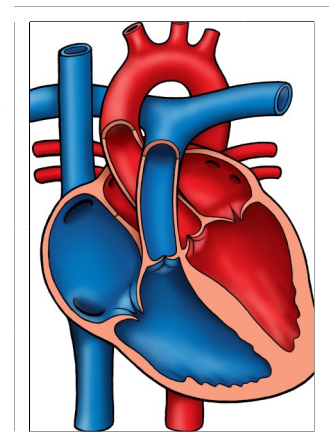


Congenitally Corrected Transposition of the Great Arteries (L-TGA)



Notes:

Normal Heart



The Children's Heart Clinic 2530 Chicago Avenue S, Ste 500, Minneapolis, MN 55404
612-813-8800 * Toll Free: 1-800-938-0301 * Fax: 612-813-8825
Children's Hospital of Minnesota, 2525 Chicago Avenue S, Minneapolis, MN 55404

Congenitally Corrected Transposition of the Great Arteries (L-TGA)

Congenitally corrected transposition of the great arteries is a rare form of congenital heart disease (occurring in < 1%) where physiologic blood flow is preserved, despite anatomic differences from a normal heart. In L-TGA, both the ventricles (pumping chambers) and great vessels (aorta & pulmonary trunk) are transposed (on the opposite side). This is because, during in-utero development, the heart turned to the left (l-looped), rather than to the right. This causes the morphological right ventricle (anatomically shaped like a right ventricle) to be on the child's left side of their heart. Likewise, the morphological left ventricle (anatomically shaped like a left ventricle) is on the child's right side of their heart. Therefore, the circulation is still physiologically normal. Blue (deoxygenated) blood returns to the right atrium, travels through the right sided mitral valve and right sided morphological left ventricle to the pulmonary artery and out to the lungs to be oxygenated. Red (oxygenated) blood returns to the left atrium, travels across the left sided tricuspid valve and left sided morphological right ventricle, and out the aorta to the body. Because the morphologic right ventricle is pumping blood to the body, instead of the morphologic left ventricle, there is added work on the ventricle. Over time, this work can strain the morphologic right ventricle leading to heart failure.

Other defects can be associated with L-TGA, such as VSD (80%), systemic valve abnormalities (tricuspid valve regurgitation (leaking), or Ebstein's anomaly) (30%), left ventricular outflow tract obstruction (pulmonary and sub-pulmonary stenosis (narrowing)) (25-50%), dextrocardia (location of heart in right chest) (25-50%), and rhythm abnormalities (due to the abnormal location of the conduction system). There is a 2% chance per year for patients with L-TGA to develop complete heart block.

Physical Exam/Symptoms:

- In the absence of other associated defects, patients are asymptomatic and may not have a murmur.
- Murmurs of VSD, tricuspid regurgitation, or pulmonary stenosis are heard if these defects are present.
- Cyanosis (blue color) can be present if there is significant pulmonary stenosis (left ventricular outflow tract obstruction) and VSD.
- May develop signs of heart failure in later years.

Diagnosics

- Chest x-ray: Abnormal heart shadow formed by ascending aorta if normal position of the heart, dextrocardia can be seen if present. Increased pulmonary vascular markings and cardiomegaly (enlarged heart) can be seen if VSD present
- EKG: Diagnostic of associated rhythm abnormality (such as atrioventricular block and supraventricular tachycardia)
- Echocardiogram: Diagnostic.

Medical Management/Treatment

- Diuretics (Lasix) are used to manage symptoms associated with excessive pulmonary blood flow and congestive heart failure (CHF).
- Medications for rhythm control or pacemaker may be indicated if heart rhythm abnormalities exist.
- Surgical approach and timing is determined by your child's specific anatomy and symptoms. Your cardiologist and cardiac surgeon will decide which surgical approach is right for your child. Please see Double Switch Operation for more information on one type of surgical repair and anticipated postoperative recovery.
- Lifelong cardiology follow up is needed
- Bacterial endocarditis prophylaxis may be needed prior to any dental procedure. For some children, this is life-long. Ask your cardiologist for recommendations specific to your child.
- Activity restrictions may be recommended depending on your child's anatomy and associated defects.

Long-Term Outcomes:

- Life expectancy is dependent upon what defects are associated with L-TGA.
- 1/3 of patients with isolated L-TGA will develop heart failure by age 45.
- 2/3 of patients with associated defects will develop heart failure by age 45.