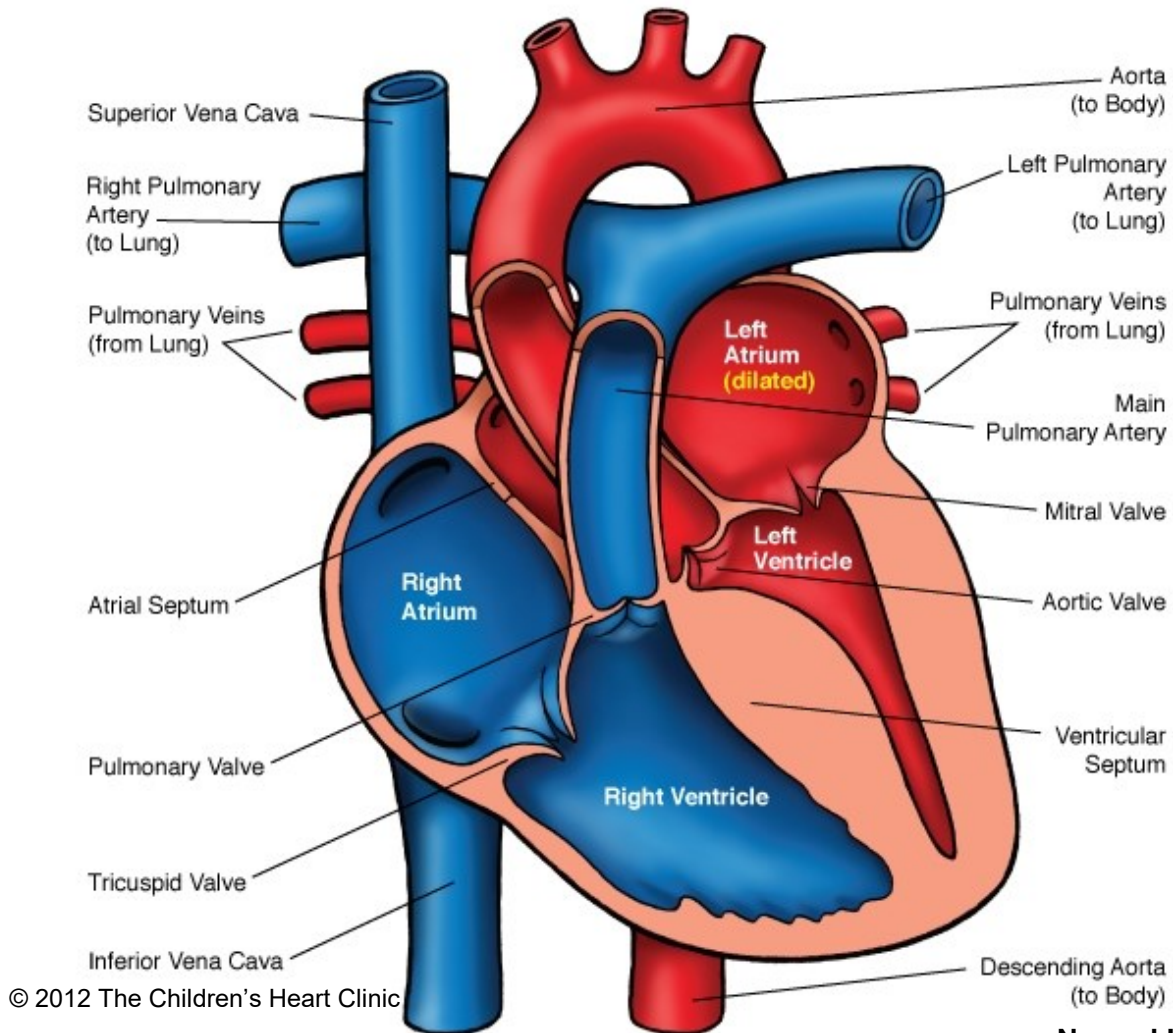
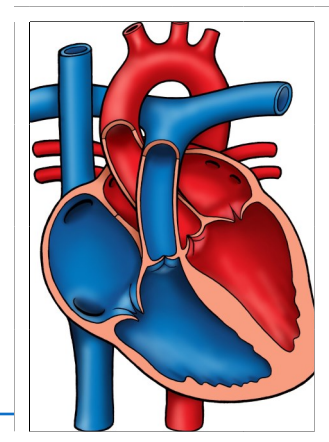


Cardiomyopathy - Hypertrophic



Notes:

Normal Heart



The Children's Heart Clinic 2530 Chicago Avenue S, Ste 500, Minneapolis, MN 55404
612-813-8800 * Toll Free: 1-800-938-0301 * Fax: 612-813-8825
Children's Hospital of Minnesota, 2525 Chicago Avenue S, Minneapolis, MN 55404

Hypertrophic Cardiomyopathy (HCM)

Hypertrophic cardiomyopathy (HCM) is a disease of the heart muscle (myocardium) in which the muscle becomes abnormally thickened (hypertrophied) without any obvious cause. HCM is often hereditary, with 60% of patients having a first degree relative with evidence of the disease. It occurs most often in adolescents and young adults with equal male/female distribution. Characteristically, the myocardium of the left ventricle (LV) becomes hypertrophied with a ventricular cavity of normal or small size. The LV becomes stiff and diastolic ventricular filling is impaired. This may lead to pulmonary venous congestion and left atrial enlargement, resulting in congestive heart failure (CHF). This form of heart disease occurs in 0.2-0.5% of the general population.

Physical Exam/Symptoms:

- Fatigue, dyspnea (difficulty breathing), palpitation, dizziness, syncope, or anginal pain.
- May be asymptomatic until sudden cardiac death.
- Systolic thrill may be palpable at the left lower sternal border or apex.
- Grade I-III systolic murmur present at the left middle/lower sternal border.
- Soft holosystolic murmur may be present (mitral regurgitation).
- Murmurs often increase in intensity with standing or Valsalva maneuver.
- *Intensity and presence of murmurs may vary from exam to exam!*

Diagnostics:

- Chest X-ray: Globular-shaped heart, normal pulmonary vasculature.
- EKG: Left ventricular hypertrophy, ST changes, abnormally deep Q waves, negative T waves, cardiac arrhythmias, or first degree heart block may be present.
- Echocardiogram: Diagnostic.
- Genetic testing

Medical Management/Treatment:

- Moderate restriction of physical activity. Cardiac clearance is required prior to participation in competitive sports.
- Clinical/genetic screening of first-degree relatives encouraged.
- Beta blockers are first line therapy, especially in those with outflow tract obstruction or arrhythmias.
- Calcium channel blockers (verapamil) may be indicated.
- Surgical septal myectomy may be performed in those who fail medical management to relieve outflow tract obstruction and improve symptoms.
- Implantable cardioverter-defibrillator (ICD) for prevention of sudden cardiac death in those at high risk.
- Cardiac transplantation if other medical strategies are unsuccessful.
- Life-long cardiology follow up and medical management.

Long-term Outcomes:

- 2-4% incidence of sudden death in patients 10-35 years of age.
- Outcomes vary depending on presence of ventricular arrhythmias, age at presentation and response to medical management.