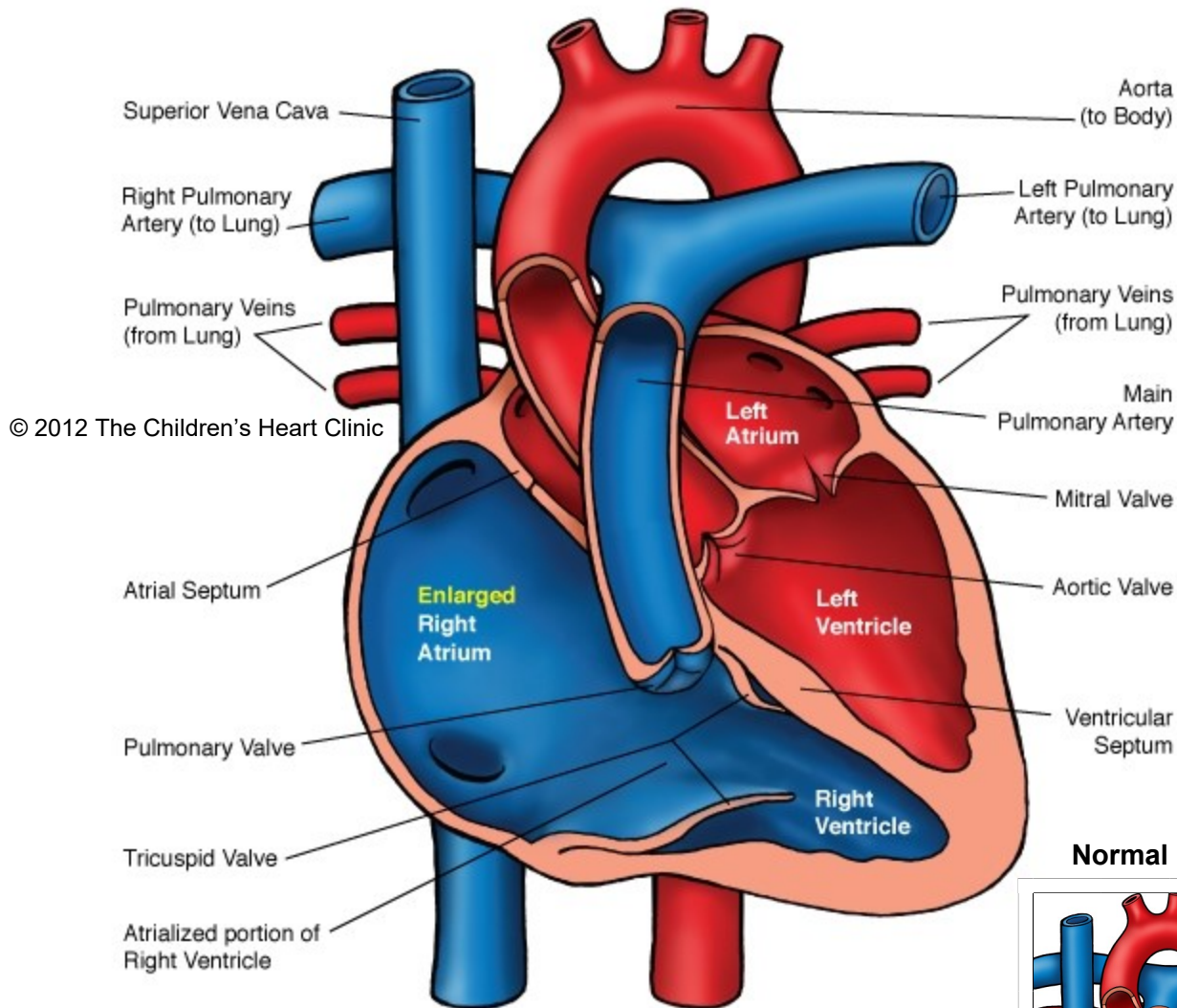
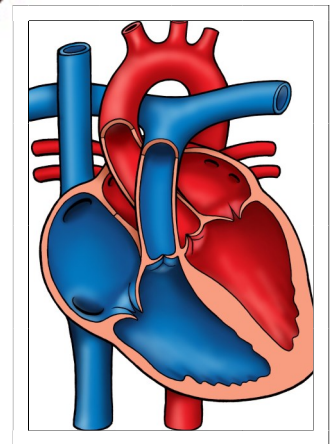


## Ebstein's Anomaly



Notes:

**Normal Heart**



The Children's Heart Clinic 2530 Chicago Avenue S, Ste 500, Minneapolis, MN 55404  
612-813-8800 \* Toll Free: 1-800-938-0301 \* Fax: 612-813-8825  
Children's Hospital of Minnesota, 2525 Chicago Avenue S, Minneapolis, MN 55404

---

## Ebstein's Anomaly

Ebstein's anomaly is a congenital cardiac defect of the tricuspid valve. The septal and posterior leaflets of the tricuspid valve are displaced downward into the right ventricular (RV) cavity. This results in a portion of the RV incorporated into the right atrium (RA), referred to as *atrialized RV*. The RV is therefore functionally hypoplastic (small and underdeveloped) and the RV free wall is dilated and thin. The tricuspid valve is incompetent and the valve leaflets are abnormal, resulting in regurgitation of blood back from the RV into the RA. As a result, the RA becomes dilated and hypertrophied. Either a patent foramen ovale (PFO) or atrial septal communication (ASD) with a right to left shunt is present in all patients with Ebstein's anomaly. Fibrosis in the RV and LV free walls is present and contributes to symptoms as well as LV dysfunction later in life. Wolff Parkinson White (WPW) preexcitation predisposes the patient to supraventricular tachycardia (SVT) and is frequently associated with Ebstein's. Pulmonary stenosis (PS), pulmonary atresia, tetralogy of Fallot (TOF), and ventricular septal defect (VSD) are also occasionally associated with Ebstein's. Ebstein's anomaly is rare and occurs in less than 1% of all congenital heart defects.

### Physical Exam/Symptoms:

- Dyspnea (difficulty breathing), fatigue, cyanosis (blue color), or palpitations with exertion in children with milder cases of Ebstein's anomaly.
- Cyanosis and congestive heart failure (CHF) may occur in neonates and young infants with severe Ebstein's.
- Clubbing of fingers and toes may be present in older infants/children.
- History of SVT may be present.
- Triple or quadruple rhythm is audible with a widely split S2. A soft, holosystolic murmur of TR and a soft mid-diastolic murmur are heard best at the left lower sternal border.
- Hepatomegaly (enlarged liver) is usually present.

### Diagnostics:

- Chest X-ray: In mild cases, the heart size and pulmonary vascular markings are normal. In severe cases, there is significant cardiomegaly (heart enlargement) and decreased pulmonary vascular markings often shortly after birth.
- EKG: Characteristically, right bundle branch block (RBBB), left axis deviation and right atrial hypertrophy (RAH) are present. 40% have first degree atrioventricular block (AV block). 15-20% have WPW preexcitation and occasional supraventricular tachycardia (SVT).
- Echocardiogram: The tricuspid valve is displaced significantly towards the apex of the heart and is a diagnostic feature of Ebstein's anomaly.

### Medical Management:

- For cyanotic newborns, prostaglandin E (PGE) therapy is needed to keep the ductus arteriosus patent for adequate pulmonary blood flow. In addition, mechanical ventilation and/or inotropic therapy may be needed prior to surgical repair.
- SVT management may include medications or ablation.
- The need, timing, and type of surgical repair is determined by severity of symptoms and success of medical management. Your child's cardiologist will discuss this with you.
- Postoperative persistent complete heart block is a rare complication that requires pacemaker placement.
- Life-long cardiology follow up is required.
- Bacterial endocarditis prophylaxis prior to dental procedures should be observed.
- Participation in competitive, strenuous sports is not recommended.

### Long-Term Outcomes:

- Children with mild Ebstein's may remain asymptomatic or mildly symptomatic and may not require surgical intervention, activity restrictions or medication therapy.
- In symptomatic patients, 18% of newborns die in the neonatal period. 30% of patients die before 10 years of age from complications of congestive heart failure.
- Arrhythmias persist in 10-20% of patients.
- Other rare, but possible complications include infective endocarditis, brain abscess, and cerebrovascular accident.