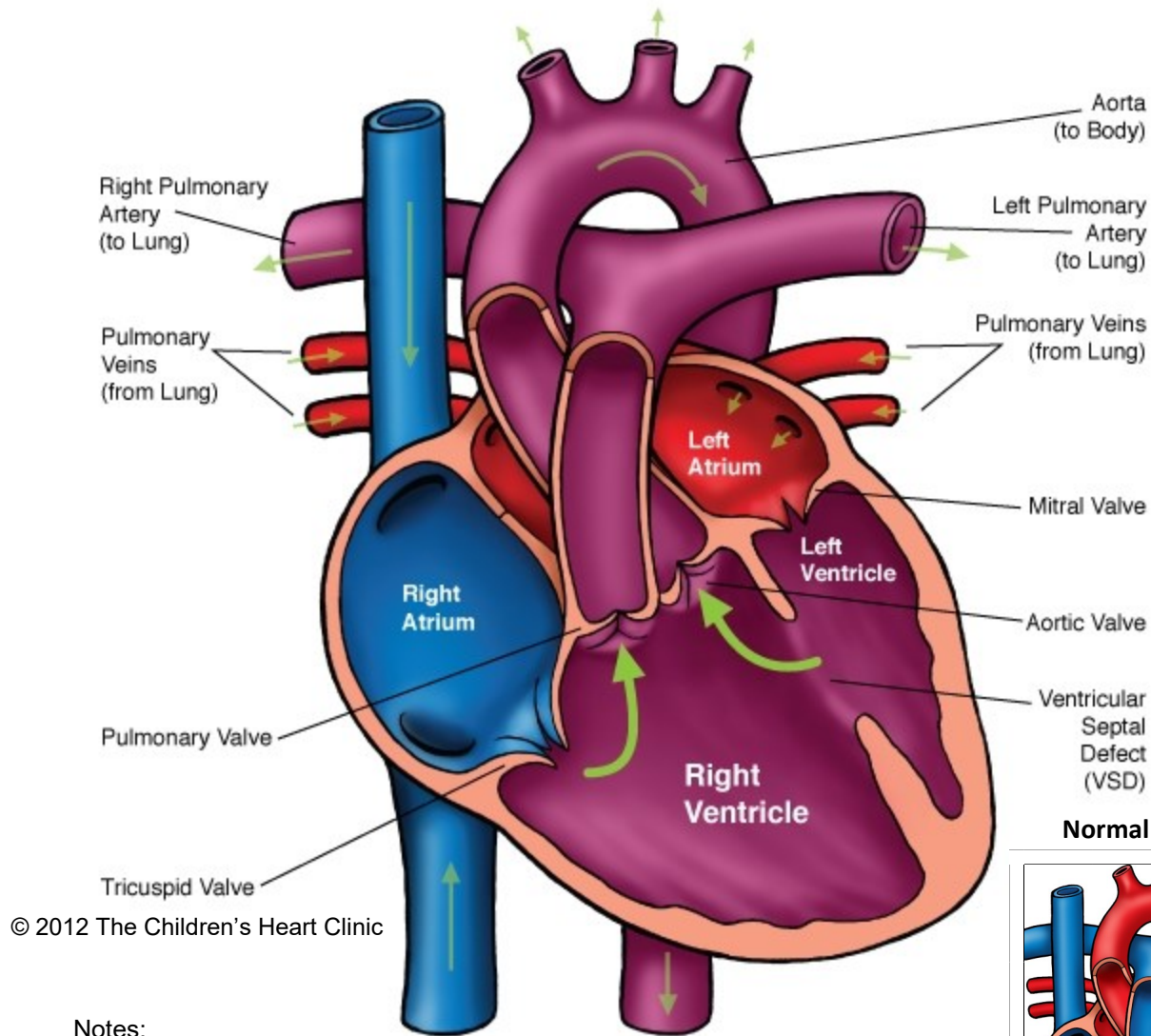
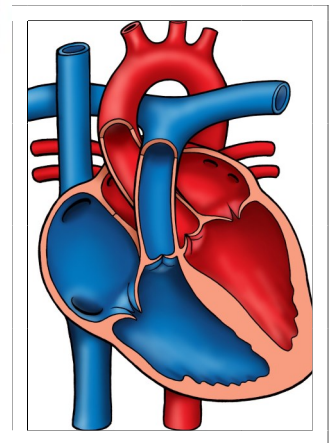


Double Outlet Right Ventricle (DORV)



Normal Heart



Notes:

Double-Outlet Right Ventricle (DORV)

In the normal heart, the pulmonary artery (PA) arises from the right ventricle and carries deoxygenated (blue) blood to the lungs to be oxygenated. The oxygenated blood travels back to the left side of the heart and is carried out to the body and organs by the aorta, which arises from the left ventricle (LV).

In double-outlet right ventricle (DORV), both the PA and aorta arise from the right ventricle. The only way for blood to leave the LV is through a large ventricular septal defect (VSD), a hole in the septum between the left and right ventricles. Typically, the great arteries are side by side and separated by conal septum. The PA most often to the left of the aorta. In the structurally normal heart, the pulmonary valve is higher than the aortic valve and the aortic valve is in fibrous continuity with the mitral valve. In DORV, the pulmonary and aortic valves are at the same level and there is no fibrous continuity between the aortic and mitral valves. There are several subtypes of DORV, based on the position of the VSD and presence or absence of pulmonary stenosis or right ventricular outflow tract obstruction (RVOTO).

Types:

- Subaortic VSD: The VSD lies to the right of the conal septum, closer to the aortic valve. This is the most common type of DORV, occurring in 50-70% of cases. RVOTO also occurs in 50% of these patients.
- Subpulmonary VSD (Taussig-Bing): The VSD lies to the left of the conal septum, closer to the pulmonary valve. This occurs in 10-30% of children with DORV.
- Doubly Committed VSD: Occurs in less than 5% of cases. The VSD is closely related to both the aortic and pulmonary valves above the crista supraventricularis.
- Noncommitted VSD: In 10% of cases, the VSD is further away from both the aortic and pulmonary valves. This type is frequently associated with atrial isomerism (atria that are structurally identical).

Physical Exam/Symptoms/Diagnostics:

With pulmonary stenosis or RVOTO:

- Cyanosis and poor growth are common.
- A grade II-III systolic ejection murmur is heard along the left sternal border.
- A systolic thrill may be present over the left mid-sternal border.
- Chest x-ray reveals a decrease pulmonary vascular markings and the heart is normal in size.
- EKG: Frequently, AV block is present. The right atria and right ventricle are hypertrophied. Right bundle branch block may be present.
- Echocardiogram: Diagnostic.

Without pulmonary stenosis or RVOTO:

- Mild or no cyanosis is present.
- Pulmonary blood flow is increased, leading to tachypnea (fast breathing), poor growth and feeding.
- Holosystolic murmur with a loud S2 and hyperactive precordium are present.
- Chest x-ray reveals increased pulmonary vascular markings, cardiomegaly (enlarged heart), and a prominent pulmonary artery segment.
- EKG commonly shows right or bilateral ventricular hypertrophy and left atrial hypertrophy. First degree AV block occurs occasionally.
- Echocardiogram: Diagnostic.

Medical Management/Treatment:

- Diuretics are used to manage symptoms associated with excessive pulmonary blood flow and congestive heart failure (CHF).
- Atrial septostomy (enlarging the hole/communication between the atria) may be needed prior to surgery to offload the left atrium and improve mixing of blue and red blood. This is done in the cardiac catheterization lab.

Double-Outlet Right Ventricle (DORV)

- Surgical approach and timing is determined by the position of the VSD and whether PS is present or not. Your cardiologist and cardiac surgeon will decide which surgical approach is right for your child. Please see [Ventricular Septal Defect Repair](#), [Arterial Switch Procedure](#), [Nikaidoh repair](#), [Damus-Kaye-Stansel Repair](#), [Right Ventricle to Pulmonary Artery Conduit](#), [Modified Blalock-Taussig Shunt](#), [Bidirectional Glenn Shunt](#), or [Modified Fontan Procedure](#) for more information specific to each type of surgical repair and postoperative recovery.
- Lifelong cardiology follow up is needed.
- Bacterial endocarditis prophylaxis is needed prior to any dental procedure. For some children, this is life-long. Ask your cardiologist for recommendations specific to your child.

Long-Term Outcomes:

- Most children with subaortic VSD without pulmonary stenosis have normal life expectancy.
- Long-term outcomes vary for other types of DORV depending on the child's surgical pathway.
- Ventricular arrhythmias may develop in the post-operative period or later in life and require medication.