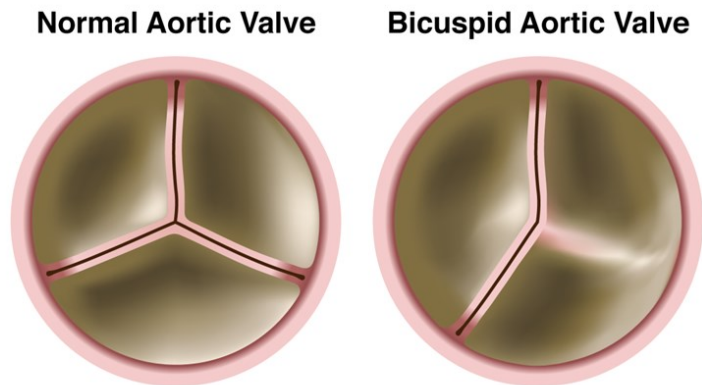
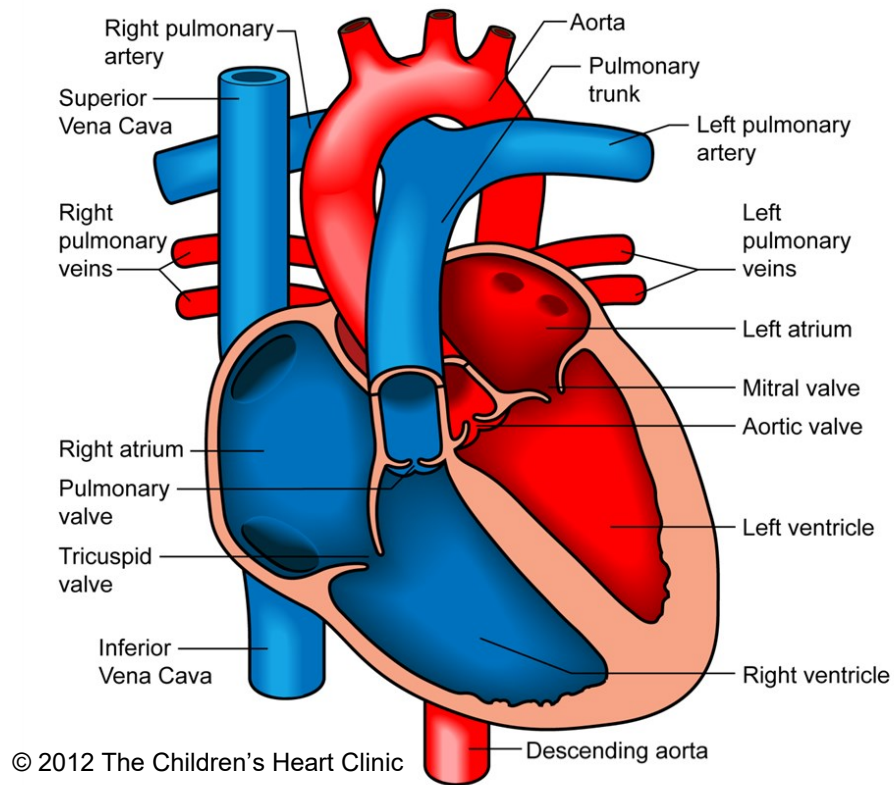


## Bicuspid Aortic Valve



Notes:

The Children's Heart Clinic 2530 Chicago Avenue S, Ste 500, Minneapolis, MN 55404  
 612-813-8800 \* Toll Free: 1-800-938-0301 \* Fax: 612-813-8825  
 Children's Hospital of Minnesota, 2525 Chicago Avenue S, Minneapolis, MN 55404

---

## Bicuspid Aortic Valve

A bicuspid aortic valve is form of congenital heart disease where the aortic valve only has two leaflets, instead of three. This typically results from fusion (joining) of two cusps of the valve along their coaptation point. A bicuspid aortic valve occurs in 1-2% of the population. It can occur alone or be associated with other left-sided heart lesions, such as mitral valve abnormalities (see [mitral stenosis](#)), or [coarctation of the aorta](#). Symptoms and presentation can vary for patients with bicuspid aortic valve depending upon the degree of stenosis (narrowing) or regurgitation (leaking) of the valve.

### Physical Exam/Symptoms:

- Most patients with bicuspid aortic valve have no symptoms (asymptomatic), unless there is associated [aortic stenosis \(AS\)](#) (narrowing) or regurgitation (leaking) (AR)
- Most children are asymptomatic with mild to moderate AS.
- Fatigue, chest pain with exertion, or syncope (fainting) may occur in severe AS.
- In critical AS, neonates develop poor perfusion, pulmonary edema (fluid retention in the lungs) within days or weeks after birth as the ductus arteriosus (see [Patent Ductus Arteriosus](#)) closes. Clinical picture may resemble that of sepsis (severe infection).
- Murmur of AS: Harsh, grade II/VI systolic murmur heard best at the second left intercostal space, with transmission to the head and neck. An ejection click may be present. An early diastolic murmur of aortic regurgitation is sometimes present in patients with a bicuspid aortic valve.

### Diagnostics:

- [Chest X-ray](#): Normal heart size and pulmonary vasculature. The ascending aorta may appear dilated.
- [EKG](#): Normal in mild cases. Left ventricular hypertrophy (enlargement) may be present in severe AS.
- [Echocardiogram](#): Diagnostic.

### Medical Management/Treatment:

- Yearly echocardiogram and cardiology visits in asymptomatic children with mild to moderate AS, more frequent in severe AS.
- Prostaglandin E (PGE) infusion to keep ductus arteriosus patent prior to catheterization or surgical intervention in symptomatic neonates with critical AS.
- [Catheterization Lab Procedure](#): Balloon dilation in the cardiac catheterization lab is often the first step in the management of neonates with critical AS or symptomatic infants and children.
- [Surgery](#): Indicated if catheter-based balloon valvuloplasty results in severe aortic regurgitation (AR) or if the pressure gradient remains high (see [Aortic Valve Replacement](#) and/or [Ross Procedure](#)).
- Lifetime anticoagulation (Coumadin and Aspirin) is needed for people with mechanical aortic valve replacements to avoid clotting of the valve.
- Life-long cardiology follow up is needed for all patients with bicuspid aortic valve, regardless of severity.

### Long-Term Outcomes:

- Stenosis may become severe over time, requiring long-term cardiology follow up and potential surgical intervention as an adult. 10-30% develop AR after balloon or surgical valve intervention.
  - Subacute bacterial endocarditis occurs in 4% of patients with valvar AS.
  - Mortality for children with valvar AS is 1-2%. Sick neonates with critical AS have a mortality rate approaching 10%.
  - Developmental outcomes vary depending on the severity of valvar disease and other co-morbidities.
  - Bacterial endocarditis prophylaxis required in patients with a mechanical aortic valve.
-