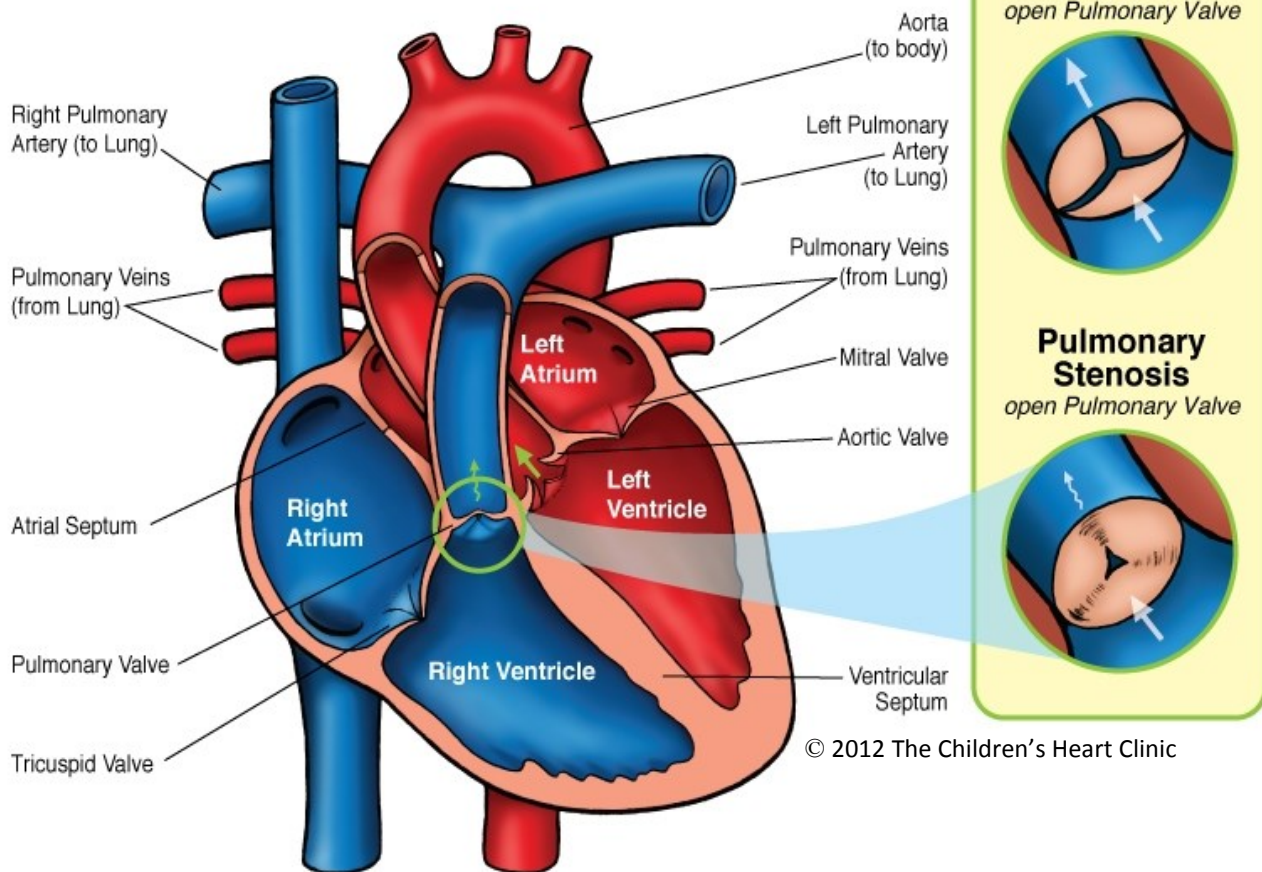


Pulmonary Stenosis



NOTES:

Children's Heart Clinic, P.A., 2530 Chicago Avenue S, Ste 500, Minneapolis, MN 55404
 West Metro: 612-813-8800 * East Metro: 651-220-8800 * Toll Free: 1-800-938-0301 * Fax: 612-813-8825
 Children's Minnesota, 2525 Chicago Avenue S, Minneapolis, MN 55404
 West Metro: 612-813-6000 * East Metro: 651-220-6000

Pulmonary Stenosis-Valvar (PS)

Pulmonary stenosis (narrowing) (PS) at the level of the pulmonary valve occurs as a result of thickened valve leaflets with fusion or absent commissures (point where valve leaflets come together) and a small valve orifice (opening). PS results in varying degrees of obstruction of blood flow out of the right ventricle. The right ventricle is hypoplastic (underdeveloped) in infants with *critical PS*, which occurs when the pulmonary valve is nearly atretic (absent). The right ventricle is normal in size for less severe forms of PS. PS as a result of thickened, irregular, immobile tissue is frequently seen in children with Noonan's syndrome. PS may occur in conjunction with Tetralogy of Fallot (TOF), Transposition of the Great Arteries (TGA), and double outlet right ventricle (DORV).

Physical Exam/Symptoms:

- Infants and children with mild PS are asymptomatic.
- Moderate to severe PS may result in exertional dyspnea (difficulty breathing), chest pain, congestive heart failure (CHF), and fatigue.
- Newborns with critical PS may have poor feeding, poor growth, tachypnea (fast breathing), hepatomegaly (enlarged liver), and cyanosis (blue color to the skin).
- Systolic ejection click and murmur are present at the left upper sternal border with a split second heart sound. The murmur may radiate to the back. The louder and longer the murmur, the more severe the stenosis.
- A mid-systolic murmur may be auscultated over the pulmonary valve with transmission to the back and axilla in children with peripheral PS.

Diagnostics:

- Chest X-ray: Normal heart size; prominent main pulmonary artery segment. Cardiomegaly (enlarged heart) may occur if CHF develops. Neonates with critical PS often have dark lung fields, indicating poor blood flow to the lungs.
- EKG: Normal in mild PS. Right axis deviation and right atrial and ventricular hypertrophy may be present in moderate to severe PS.
- Echocardiogram: Diagnostic.

Medical Management/Treatment:

- Newborns with critical PS require medication to keep their ductus arteriosus patent called prostaglandin E1 and balloon valvuloplasty in the catheterization lab to provide flow through the pulmonary valve shortly after birth.
- Surgical repair/replacement may be necessary in all cases for children with moderate, severe, or critical PS.
- Activity restriction required only for patients with severe PS.
- Long-term cardiology follow-up and periodic echocardiogram will be needed to follow PS, even after surgical or cath lab intervention.

Long-Term Outcomes:

- Severity of PS does *not* tend to increase for infants/children with *mild* PS.
- Severity *does* tend to increase for infants/children with moderate to severe PS.
- Long-term outcomes vary depending on pulmonary valve function and the presence or absence of other heart disease or co-morbidities.
- Bacterial endocarditis prophylaxis may be indicated in patients who've had their pulmonary valve replaced.